

**PATIENT**

Bubblesf Treptau

SPECIES

Canine

BREED

Shih Tzu

SEX

Female Intact

AGE

3 months

WEIGHT

5.2lbs

INTERPRETED BYMaggie Machen Lamy,
DVM, DACVIM
(Cardiology)**IMAGING PERFORMED BY**

Kim Liedberg

PRESENTING CLINICAL SIGNS

History: "Machinery" murmur ausculted.

ECHOCARDIOGRAM FINDINGS

2D, m-mode, color flow and doppler imaging is available. Continuous flow detected with color Doppler in the pulmonary artery in the region of the ductus arteriosus. High velocity shunt primarily L-R suspected. Moderate volume overload of the left heart with adequate systolic function. Increased LV sphericity. Mild LA dilation. Mild central MR. No obvious TR. Normal pulmonic outflow velocities; no pulmonic insufficiency. MPA and branch dilation. The PV appears normal. Mildly elevated aortic outflow velocities with trace AI. No pericardial or pleural effusion noted. No obvious cardiac masses.

CARDIAC CHART

CANINE CARDIAC PARAMETERS	MR VMAX (m/s)	TR VMAX (m/s)	LA/AO (Boon method)	LA/AO (Heart Base; Swe)	FS (%)	EF (%)	EPSS (cm)	
NORMAL PARAMETER	4.5-5.5	<2.7	1.3	<1.6	28-40	40-100	<0.6	
PATIENT	NA	NA	1.3	1.4	38	69	0.5	
CANINE CARDIAC PARAMETERS	HR (BPM)	AV VMAX (m/s)	PV MAX (m/s)	BODY WEIGHT (kg)	LA 2D short axis Base view (cm)	LVIDd Avg; 2D and m-mode short axis (cm)	LVIDs Avg; 2D and m-mode short axis (cm)	
NORMAL PARAMETER	50-100	0.7-1.7	0.7-1.6	BELOW	BELOW	BELOW	BELOW	
PATIENT	174	1.6	1.0	2.4	1.6	2.9	1.8	
*Normal chamber parameters expressed as a mean value (SD)					3	1.27 (5.3)	2.46 (2.46)	1.36 (5.5)
BODY WEIGHT DEPENDENT PARAMETERS					5	1.40 (4.5)	2.74 (5.2)	1.60 (4.7)
<i>*Note: All measurements based upon multi-modal images and methods. An average value is reported.</i>					10	1.50 (3.8)	3.27 (3.5)	2.06 (3.1)
					15	1.83 (2.0)	3.71 (2.4)	2.43 (2.1)
					20	2.02 (1.9)	4.14 (2.2)	2.80 (2.0)
					25	2.18 (2.4)	4.48 (2.9)	3.10 (2.5)
					30	2.33 (3.3)	4.83 (3.9)	3.39 (3.4)
					35	2.48 (4.3)	5.17 (5.0)	3.69 (4.5)
					40	2.62 (5.2)	5.48 (6.1)	3.96 (5.4)
					50	2.88 (7.1)	6.07 (8.3)	4.46 (7.4)

INTERPRETATION OF THE FINDINGS & FURTHER RECOMMENDATIONS

The cause of the murmur is a patent ductus arteriosus (PDA). This is a congenital condition where a blood vessel present in the fetus remains open after birth. When patent, this allows blood to recirculate through the lungs inappropriately and volume overloads the left heart chambers as is seen here. There is also trivial MR and AI, however these are clinically insignificant at this time. It is important to note that other small congenital defects can be easily missed in these cases, and advanced imaging with a Cardiologist is recommended.

Given LA/LV dilation, this patient is at risk for progression to CHF, arrhythmias, PDA reversal due to development of pulmonary hypertension, exertional syncope, and/or sudden death at home in the future. Monitor sleeping respiratory rates at home to screen for progression to CHF.

HOSPITAL NAME

SVS Imaging WI

REFERRING VET

Dr. Rudawski

INVOICE

30110

DATE

4/6/23

IMAGING PERFORMED BY

svsmobileimaging.com 309-737-3070

**Clinical Sonography & Telecytology**

EDUCATIONAL TELECONSULTATION SERVICES™

1-800-838-4268 info@sonopath.com SonoPath.com

PATIENT

Bubblesf Treptau

SPECIES

Canine

BREED

Shih Tzu

SEX

Female Intact

AGE

3 months

WEIGHT

5.2lbs

INTERPRETED BYMaggie Machen Lamy,
DVM, DACVIM
(Cardiology)**IMAGING PERFORMED BY**

Kim Liedberg

HOSPITAL NAME

SVS Imaging WI

REFERRING VET

Dr. Rudawski

INVOICE

30110

DATE

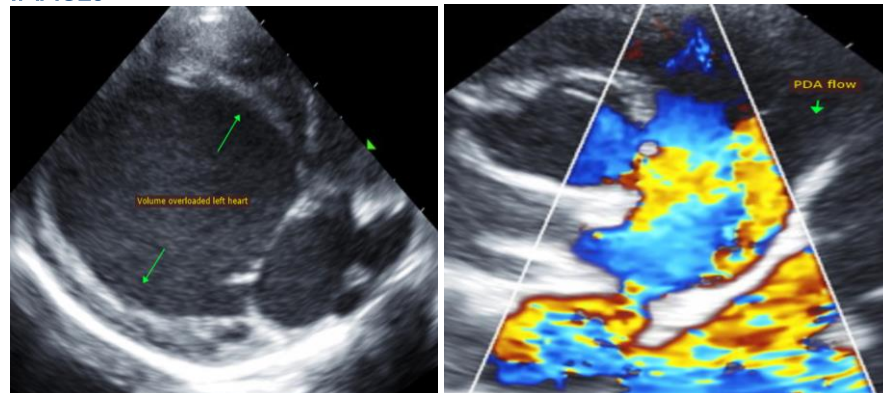
4/6/23

Gold standard therapy is surgical closure of the vessel. This can be done interventionally or through a thoracotomy, and consultation with a local Cardiologist is recommended if sought (**highly recommended**). Success rates for the procedure are generally high, particularly given the asymptomatic status and a good chance for a normal life if closed appropriately. Regardless of whether or not surgery is elected, cardiac support with Pimobendan is recommended for long term benefit. If surgery is not an option, prognosis is guarded to poor long term and close monitoring is advised.

Omega fatty acid supplementation and mild salt restriction may be of some long term benefit. Monitoring of sleeping breathing rates is recommended as the best way to screen for progression to CHF at home. Mild activity restriction is advised. Monitor at home for breathing changes, worsening cough, fainting episodes, exertional dyspnea.

PLAN

Institute Pimobendan 0.3mg/kg PO q12h. Recommend referral to a local Cardiologist for surgical consultation. If not an option, reassess structure and function every 6 months lifelong to assess need for additional medications, sooner if clinical signs arise (progressive cough, labored breathing, syncope).

IMAGES

The information and recommendations provided are based on the images presented by the referring veterinarian. No evaluation can be communicated regarding pathology that was not visible in the image/video clips provided.

Thank you for this referral. If the clinical or image interpretation does not parallel your findings or if I can be of any further assistance, please contact me.

Maggie Machen Lamy, DVM

Diplomate of the American College of Veterinary Internal Medicine (Cardiology)

info@sonopath.com